

Injury documentation: Using the BALD STEP Mnemonic and the RCMP Sexual Assault Kit

By Cathy Carter-Snell, RN, PhD, ENC-C, SANE-A,
Forensic Studies Program, Mount Royal University,
Calgary AB

Abstract

Injury assessment, nomenclature and documentation vary widely across emergency departments. The Royal Canadian Mounted Police (RCMP) has forensic laboratories across Canada and performs the majority of testing of evidence for Canadian victims of sexual assault outside of Ontario or Quebec. Most emergency nurses are familiar with the large box the RCMP officers bring for the documentation and collection of evidence after sexual assault. Fewer are familiar with the inner contents of the kit or documentation. The sexual assault kit and documentation are now undergoing change, with a new kit soon to be released. The RCMP forensic laboratories identified the need for kit changes due to equipment updates and research related to quality and best practices. Some health care professionals across the country and representatives of Making a Difference Canada were consulted for suggestions on documentation and kit contents. Mount Royal University's Forensic Research Network (www.mtroyal.ca/forensicresearch) will be developing free educational materials on the kits and use of contents in preparation for the release of the new kits (hoped to be late 2011, but not yet determined). In the meantime, the focus of this article is to introduce emergency nurses to a few key changes in documentation and evidence collection they may anticipate. The largest of these changes is the adoption of a mnemonic phrase to aid in standardization of injury documentation and assessment known as BALD STEP.

Assessment and documentation of injuries and physical findings after an examination are extremely important, both to provide a baseline for determining care priorities and for potential legal proceedings. Presence of recorded injuries is a key factor in sexual assault prosecution even though at least 1/3 of women have no injuries at all after sexual assault (Carter-Snell, 2007). A major challenge in injury documentation is inconsistencies between departments in the types of injuries recorded and the terms used for the injuries. The rates of injuries reported, therefore, vary. Rates of non-genital injuries across sexual assault studies range from 23% to 76%, and genital injury rates from 5% to 85% (Carter-Snell,

2007). Not everyone included redness, swelling, or tenderness in their list of injuries in the research, often due to inconsistencies in quantifying these for research purposes. Another source of variation was in the techniques used to visualize injuries. Rates of genital injury were three times higher in the studies where the examinations were conducted by sexual assault nurse examiners (SANEs) compared to emergency physicians. The studies involving emergency physicians did not include aids to visualization like toluidine or colposcopy, while most of the SANE studies did include these aids. Experience with sexual assault examinations has also been linked to injury identification. Not all emergency physicians have experience with sexually assaulted patients. In contrast, most emergency physicians are experienced with body trauma assessment. In the same systematic review, the rates of non-genital injury were twice as high when assessed by emergency physicians compared to the rates in studies with SANE assessments. The review also showed incorrect and inconsistent terms in use for the same injuries (e.g., bruising and ecchymosis; cut and laceration). The use of a standard range of potential findings and consistency of terminology will allow us to better understand rates of injury with sexual assault or intimate partner violence and will provide a guideline for assessment among those staff who do not conduct these examinations regularly. This was the objective when looking to improve the RCMP documentation, and the advisory group and the RCMP laboratory decided to adopt the BALD STEP mnemonic developed by Carter-Snell in 2005 to teach forensic assessment.

BALD STEP mnemonic

Sexual assault nurses have often used the TEARS mnemonic (Girardin, Faugno, Seneski, Slaughter, & Whelan, 1997; Slaughter, Brown, Crowley, & Peck, 1997) to represent tears, ecchymosis, abrasions, redness and swelling. While this has been useful as a beginning standard, it omits a number of key injuries or physical findings and uses terminology that is now outmoded (ecchymosis and tears). One of the patients the author vividly recalls identifying as a victim of violence was brought in to emergency by her husband—she held up two misshapen wrists, each with parallel linear red marks across them. When asked what happened, her husband stepped in to tell us she had slipped on a bald (worn) area of carpet on their stairs in their home and had fallen all the way down. Her x-rays revealed bilateral fractured wrists and, combined with the bruises to her wrists, the history and localized injuries did not match the pattern one would expect if she fell in that manner. The need for an index of suspicion, comprehensive injury assessment, and the reminder of this woman combined to form the BALD STEP mnemonic as shown in Figure 1. The mnemonic can be used for assessing any emergency patient who sustains assault or trauma.

Most of the findings in BALD STEP are injuries from blunt mechanisms (bruises, abrasions, avulsions, lacerations, deformities, swelling, tenderness and erythema and petechiae). Penetrating injuries and mixed injuries (i.e., bite marks) are also

BALD STEP Mnemonic for Physical Findings	
B BI bitemark	S SW swelling
BL bleeding	ST stain (+ FL if Fluorescent)
BR bruise	T TE tenderness to palpation
BU burn	TR trace evidence (+ specify type)
A AB abrasion	E ER erythema
AV avulsion	P PA patterned (draw shape)
L LA laceration	PT petechiae (draw region/spread)
D DE deformity (acute)	PE penetrating (+ I incised, S stab, P puncture, G known gunshot)

Indicate characteristics (e.g. shape, size, colour) beside each injury

Carter-Snell, C. (2011). Snellconsulting.org OR cartersnell@shaw.ca. May be reproduced.

Figure 1. BALD STEP Mnemonic

included, as well as patterned injuries. The mnemonic also includes physical findings that may be of relevance such as bleeding, trace evidence and stains. Some key points regarding these findings are summarized in the following sections.

a) Bruising and blunt force

Bruises and tenderness are often found after blunt force trauma. Bruises vary widely in appearance, both in colour and in patterns. They may be deep and not appear on the surface of the skin for two to three days, or may be red, blue, or purple if relatively fresh. There is no reliable way to age a bruise since factors such as age, metabolism, skin condition, medications and body temperature can all affect the progression of bruise colours and appearance. Careful documentation of the colour is important, however, as an expert may be able to interpret these findings to some degree. For instance, if yellow is present the breakdown of hemoglobin has begun and the bruise will be at least 18 to 24 hours old (Bariciak, Plint, Gaboury, & Bennett, 2003; Langlois & Gresham, 1991; Mosqueda, Burnight, & Liao, 2005; Stephenson & Bialas, 1996). On the other hand, some bruises never turn yellow, and a blue or purple bruise may still be as old as or older than another person's with yellow present. Patients should be reminded that the appearance of a bruise will change over time and if they find new bruises or they worsen in appearance they should return for reassessment and documentation or have the police photograph the new injuries.

Erythema (redness) is considered a non-specific finding rather than an injury, as it may be caused by many mechanisms other than trauma. Some aspects of redness may suggest, however, that it is an injury in its early stages. These include redness that does not disappear with repositioning or with application of pressure, tenderness to palpation, location in an area consistent with the patient's history of contact, patterning, or if it is focal (localized to one spot) rather than generalized.

Deep bruises may only be noticed by the presence of tenderness to palpation in some cases. Tenderness is considered more objective than reports of pain, since tenderness is determined by the patient's reaction to palpation such as grunts, grimaces, groans or withdrawal. Pain is self-reported and does not involve touch. Only 18% of women with physical injuries reported having any pain across the research, while 47% had tenderness to palpation (Carter-Snell, 2007). It is, therefore, very important to include palpation for tenderness in the assessment and documentation, as well as gross visual inspection from head to toe.

The terms "bruise" and "ecchymosis" should not be used interchangeably. Although their end result is the same (i.e., leakage of blood into the interstitial tissues), the mechanism is quite different. Ecchymosis is now recognized as being from medical reasons such as vascular disorders that affect the movement of blood out of the blood vessel walls (Sheridan & Nash, 2007). In contrast, bruises are the result of blunt forces being applied to the area, mechanically disrupting and damaging the blood vessel walls.

b) Swelling, compression or application of significant force

Application of blunt force may result in swelling. This is another non-specific finding, as swelling may be from multiple factors. Swelling is difficult to quantify reliably between staff—what is significant swelling to one nurse may be moderate to another. For

this reason, swelling is generally excluded from injury research. It does not mean, however, that it is not to be documented or is unimportant. Like erythema, swelling may be an indicator of trauma, particularly if it is focal or consistent with the location of trauma.

Petechiae are collections of small red spots usually less than 1 mm to 2 mm in diameter (Gall, Goos, Payne-James, & Culliford, 2003). These are the result of the rupture of venules, typically from compression such as strangulation or having a heavy object on top of the body. Petechiae will form in any area above the compression, particularly in mucous membranes such as the mouth or eyes. For instance, patients who were trapped under debris and heavy equipment in a tornado showed patches of petechiae in all areas above the area of compression. In areas where the capillaries and venules are close to the surface with little superficial tissue you may also see petechiae with blunt trauma (e.g., on the cervix with impact of the penis), or with suction (e.g., "hickeys"). Petechiae do not blanch when pressure is applied. Other non-trauma causes of petechiae should be ruled out such as subconjunctival petechiae seen with vigorous coughing, side effects of marijuana use, fat embolism, radiation, bone marrow malignancies, viral infections or platelet abnormalities.

Bones may fracture if sufficient force is applied in comparison to bone strength. Diagnosis of fractures is out of the scope of most nursing practice and typically requires x-ray confirmation. During assessment of closed fractures, however, nurses may notice an acute deformity of the bone or joint and with palpation we may even feel a bump or "step" (a "step deformity"). In the BALD STEP we are referring only to acute rather than chronic deformities or disabilities.

c) Breaks in skin integrity

Breaks in skin integrity may result in increased risks of infection for the patient and may affect decisions regarding prophylaxis such as HIV medications. Examples of injuries include abrasions, avulsions, lacerations, and penetrating injuries.

An abrasion is the most superficial of the breaks in skin and is the result of blunt injury. The top layer of skin (epidermis) are removed either from pressure such as being held, or from friction such as fingernails or movement across a rough surface. Typically there is little or no bleeding unless deeper dermal papillae are disrupted. Underlying tissues such as connective tissue remain intact.

An avulsion results when skin or tissue is peeled back. Examples of avulsions are removal of toenails if the foot is caught, fingernails being removed by an abuser, teeth being removed or part of the scalp being peeled back if hair is caught in machinery.

A laceration is from blunt forces. It occurs when the tensile strength of the skin is exceeded. This may be from too much force or fragile tissues (e.g., thinning layers or loss of connective tissue with aging). The edges of the skin literally tear apart. Characteristics include ragged, uneven wound edges and often cross-bridging of hairs or connective tissue in some parts of the wound. There may be abrasions at the wound edges and debris. Lacerations are often incorrectly called "cuts" by emergency staff, but the mechanisms are quite different. Genital lacerations are typically quite small (e.g., 0.5 cm to 1 cm) on the fossa navicularis or posterior fourchette and may sometimes be missed if not

familiar with their appearance. Application of toluidine 1% dye to the area is helpful to confirm the presence of lacerations. After swabs of the labia are obtained for the kit, the dye is applied to external genital regions with a cotton-tipped swab, or is available in pre-loaded applicators (National Forensic Nursing, 2006). The dye is taken up by exposed nucleated cells that are underneath the epithelium when skin is torn. Abrasions do not generally extend into the nucleated layers, so do not typically take up the dye unless deeper. After 60 seconds the dye is removed gently from the area either with either water-soluble lubricant or 1% acetic acid wash and wiping gently with gauze. Any areas of concentrated deep purple are most likely lacerations. If diffuse pale purple colouring remains despite attempts to remove it, this is likely a non-specific finding, as there could be many causes for it such as irritation (e.g., panties, yeast infections).

Penetrating injuries are most often either incised (cut) or stab type wounds. Both have more even edges and, if deep enough, will cut through connective tissue. There is usually some bleeding although it may be dried by the time of arrival. An incised or cut wound is wider than it is deep, as the knife cuts across the skin. In contrast, a stab wound is deeper than it is wide, with the penetrating object going deeper into the tissue. There may also be markings of the hilt of the knife or handles around the opening. Gunshot wounds will differ in appearance depending on the type of weapon, the type of ammunition and the distance between the weapon and the victim. If closer contact, there may be a burn around the point of entry and a more symmetrical penetrating wound. With more distance, there is often tattooing of gunpowder or shot and the wound is a little less symmetrical. At far distances, there may only be a slit or could be only buckshot spread and no central wound visible. Even experienced trauma surgeons mislabel exit and entrance wounds (Apfelbaum, Shockley, Wahe, & Moore, 1998). This can lead to incorrect conclusions and even convictions, so these terms should be avoided. Simply describe the wound characteristics and leave it to the experts. It may also not be known that a gun was involved if the patient was brought in unconscious and the wound is not obvious. In that case, call it either a stab or puncture and carefully describe the characteristics.

d) Other findings

Trace evidence may be on the patient's body or clothing. Examples include loose hairs or debris. These should be collected and placed into a paper envelope. Sharp debris such as glass or a needle should be placed in a container that won't puncture such as a urine container. There may also be stains visible on the skin. If these are dry and there is residue, you may be able to scrape the residue into a paper envelope with a tongue depressor or microscope slide. If not, then use a wet swab to wipe the entire stain area and store it according to the kit directions. If the stain is wet, a dry swab can be used.

Some departments have an alternate light source (>400 nm wavelength) or an ultraviolet light (<400 nm). Ultraviolet lights will fluoresce with many non-relevant substances so are of little value. Alternate light sources are of some value, but not essential. Under certain circumstances semen stains may fluoresce if a wavelength greater than 450 nm is used (Nelson & Santucci, 2002). Absence of fluorescence, however, does not mean semen stains are not present. The area should still be swabbed if there is a history of ejaculation, sucking, biting or licking in that area. Ultraviolet and alternate light

sources have also been shown to sometimes reveal deep bruises and bitemarks that are not visible in ambient light (Golden, 1994; Lynnerup, Hjalgrim, & Eriksen, 1995; Vogeley, Pierce, & Bertocci, 2002). If an ALS is available, the head-to-toe examination should be conducted first with the ALS in a darkened room to allow taking wet/dry swabs of any stains that fluoresce before they may be disrupted with palpation. Then the head-to-toe examination is repeated with inspection and palpation with the room lights on.

Bleeding should also be noted from any site, including whether it is active or dried. It is also helpful to note any signs of healing such as serous fluid, granulation tissue or scar tissue formation. This information will help an expert to interpret the injuries.

Burns may be thermal, electrical or chemical. Regardless of the cause, there will be some disruption to the skin. There may be erythema, blistering, or loss of various thicknesses of skin, ranging from partial superficial or partial thickness to full thickness. Look for symmetry of burns, clear lines of demarcation such as water lines or patterned burns. These may suggest non-accidental burns.

Documentation with BALD STEP

The key principle in injury documentation after trauma or assault is to remain objective. Only chart the injuries (e.g., BR, AB) or findings and relevant characteristics such as colour or size. Avoid interpreting the injury (e.g., "fingertip bruises" or "fresh bruise") or cause of the injury (e.g., "slap" or "belt") even if the patient has indicated the possible object. This is for the experts to interpret if qualified by the court. It is also important to avoid subjective determinations such as "small", "moderate" or "large"—instead provide measurements, landmarks or comparisons to a bilateral part. For instance, when explaining a swollen eye, perhaps describe how much farther forward the eyelid protrudes than the non-injured eye or measure the differences in wrist size with a swollen wrist.

The new RCMP documentation will have the BALD STEP mnemonic appear on the same page as the body Traumagram to act as a key. An example is shown in Figure 2, although the final version on the RCMP documents may differ slightly. The first few initials of each finding are used as a way to shorten documentation while ensuring all findings are included. Any additional characteristics can be added beside the initials such as size, colour, shape, or signs of healing. Although it is only included on the body Traumagram the BALD STEP mnemonic is also applicable to the genital Traumagram or other detailed Traumagrams available (e.g., hand, face).

Consistency of documenting all findings is important. Some findings clearly occurred prior to the assault or trauma, such as a fully healed scar or a tattoo and can be recorded as such. The extent of documentation of characteristics required in your department will depend on local procedures. Some departments choose to indicate the finding and write "old" beside it, and not include measurements or characteristics. Invariable nursing practice should then be that if the term "old" is used, the patient has indicated that the injury or finding was there prior to the assault (e.g., BR-old). Similar practice can be used for scars or tattoos—note location but not size.

The advantage of the BALD STEP mnemonic is that it reduces charting while increasing the breadth of injuries and physical find-

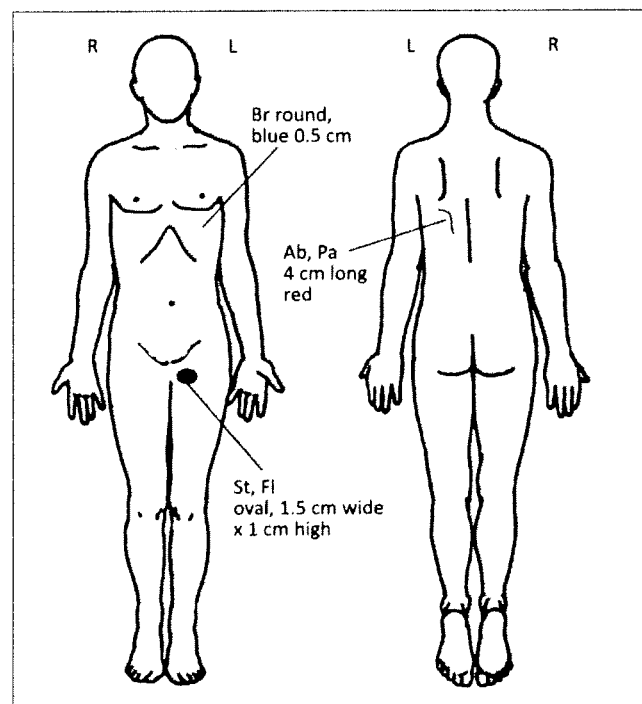
ings you include in the assessment and standardizing charting. There is no need to include negative charting. Narrative charting is only required if further explanation is required rather than repeating each injury identified. In the narrative charting you may simply state, "Inspected and palpated from head to toe in ambient light, BALD STEP findings are shown on Traumagram." This will reflect that you assessed for each of the findings and only recorded those found. The same may be done with the genital exam. Make this your invariable practice and you will only need to use narrative notes to record any deviations from this practice.

There are a few clarifications related to the use of the BALD STEP abbreviations to note:

- **Patterned injuries:** include the abbreviation beside the appropriate injury (e.g., BR-PA) and the characteristics such as size, shape, colour of the injury. If there is a patterned injury then draw it onto the Traumagram, indicating PA beside it and the type of injury (e.g., PA-BR) and the dimensions along with other characteristics. Examples would be a bite mark shape, an oval injury or a crescent shape. If the pattern won't fit on Traumagram, note the location and draw a box on the white space in which you can re-create the pattern, then clearly note the dimensions and other characteristics within the box. Patterned injuries approximate the shape of an object although may not be exactly the same due to differences in skin, dispersion of blood and tissue compression. Pattern of injury is not the same as patterned injury. Pattern

of injury is a collection of injuries that would be expected given the mechanism and guide the focused assessment (e.g., with a fall from heights you expect spinal injury and injuries at points of impact; with strangulation you expect petechiae, difficulty swallowing/hoarseness, potential loss of consciousness and incontinence). You may use cross-hatching on the diagram to indicate the area of spread of injuries such as petechiae, erythema or patterned injuries.

- **Stains:** may be visible in ambient light. They would be recorded as ST with descriptions (e.g., colour, size, shape). If the stain or bruise is only seen when it fluoresces with a light source then it would be ST-FL or BR-FL.
- **Lacerations:** if using toluidine to help confirm presence of genital lacerations or bite marks to the breast then it should be noted if the laceration is seen with or without the toluidine or both. An example would be "LA-with & without toluidine" or "LA-only with toluidine."
- **Penetrating injuries:** are noted on the RCMP documentation, but the associated descriptors do not appear to be included: I for incised, S for stabbed or P for puncture (could add G for gunshot). You can document one of two ways: write these descriptor initials and their meaning onto the Traumagram and record as PE-I, PE-S or PE-P; or on the Traumagram write PE-incised, PE-stab or PE-puncture. Again, include descriptors such as burns or abrasions on edges, size, and bleeding.



BALD STEP Mnemonic for Physical Findings

B BI bitemark	S SW swelling
BL bleeding	ST stain (+ FL if fluorescent)
BR bruise	TE tenderness to palpation
BU burn	TR trace evidence (+ specify type)
A AB abrasion	E ER erythema
AV avulsion	P PA patterned (draw shape)
L LA laceration	PT petechiae (draw region/spread)
D DE deformity (acute)	PE penetrating (+ I incised, S stab, P puncture, G known gunshot)

Indicate characteristics (e.g. shape, size, colour) beside each injury

It is likely that sexual assault teams with existing documentation and consent forms may be able to continue to use their own documents, as long as the evidence is catalogued and principles are maintained. Some teams have more extensive consents and have already incorporated the BALD STEP mnemonic. There are concerns that for those teams who have not incorporated the BALD STEP there will continue to be variability in the range of injuries and findings recorded or the terminology.

The RCMP kit also comes with useful labels to use for any documentation or evidence. Each label in a kit has a unique number and numerous labels with the same number. These are placed on documents, evidence records and evidence samples to ensure they can be identified and linked to the patient.

Proposed contents of the RCMP kit

There are a number of other changes to anticipate with the kit. Although not all recommendations were implemented from the advisory group, the kit will offer a number of key improvements. There are discussions of developing an end-user evaluation to seek your input as you use the kits and that further changes may be made. The main purpose of the kit changes were for the laboratory to simplify the range of evidence collected, to ensure procedures are based on maximum recovery of evidence and best practices and to standardize evidence collection and equipment. It has not been decided whether those teams who have their own kits (e.g., urban centres) will be able to buy the same equipment for their own kits or whether they will have to buy the entire RCMP kit.

A sexual assault kit can only be sent to the forensic laboratory if authorized by the police. Some departments have storage and procedures to collect kits on all assault victims and store them until the victim decides if they want to report (e.g., "third option" or "anonymous kits"), but the police will still need to be involved

Figure 2. BALD STEP and the Traumagram

for the kit to be analyzed. Regardless of the situation, informed consent must be obtained from the patient to conduct a physical examination for effects of assault, to collect evidence and samples, and to share information with the police if involved.

Two key points in evidence collection include avoiding contamination and chain of custody. Always wear gloves and change them frequently, as even a minor break can cause your own DNA to be detected and replicated millions of times in the laboratory! Do not allow samples from different regions to touch each other to avoid cross-contamination during evidence collection. Chain of custody is established if you can account for everyone who has had contact with the kit and the whereabouts of the kit at all times. Once the kit is open, it must remain with you and be visible. If you step out of the room, take the kit with you or assign a teammate to remain with it so there can be no question of someone inserting something into it or altering the evidence. The officer should not be in the room during the physical examination due to privacy of health information, but will have concerns about chain of custody. Assuring police that chain of custody will be maintained is important. Once the kit is complete, hand it directly to the officer. You (or the physician conducting the examination) will review the samples contained in the kit with the officer and sign for transfer of these on an evidence record.

It is important to use the history of the assault to carefully direct your head to toe examination for injuries and to select which samples will be collected—not all are needed with each patient and may cause unnecessary distress. If the patient changed their clothes between the assault and now, there is no need to include clothing. If there was no history of anal or oral penetration, you may not want to do the rectal swab or the oral swab respectively. It is important, however, to collect the sample anyway if the person was unsure of contact (e.g., breast sucking, anal penetration) due to intoxication or unconsciousness.

The proposed contents of the new kits are as follows:

- Paper bags for clothing that may contain evidence (e.g., panties)
- Sterile plastic vials for debris on body
- Swabs for stains, bite marks—the type of swab used (“Cap-Shure”) allow for air flow through and around the lid so some air drying of sample occurs within the container
- Paper envelope for cut scalp or pubic hair samples (ONLY cut if there is debris on hair such as semen)
- Sticks for scraping under fingernails (right and left hand) if there is a history of the patient scratching the assailant and paper to place under the hand while scraping, then bundle with the stick
- Swab for oral sample of teeth/gum line IF there was a history of oral-penile penetration. Once this swab has been taken the patient can drink or eat if there are no other medical contraindications
- Lancet, FTA paper, dessicant, Mylar envelope, and non-alcohol cleansing wipe to obtain the DNA blood reference sample from patient with a finger prick after cleansing site. Only one of the quarter-sized circles on the FTA paper needs to be filled (an alternate is to use a butterfly/scalp vein connector for venipuncture if other samples are required and then to fill the FTA circle with the blood remaining in the tubing). The FTA paper is placed in the envelope with the dessicant

- White paper and a comb with embedded cotton batting for pubic hair combing—the paper is placed under the patient’s buttocks and comb down once on each side (if there is pubic hair). Fold the comb inside the paper to enclose any debris or loose hairs that may fall onto it and place in the accompanying envelope. If a blood sample cannot be obtained either through venipuncture or finger prick then a buccal swab may be obtained as long as there is no history of oral-penile penetration. For a buccal swab, take one of the extra swabs supplied and rub it on the inner cheek on each side to obtain epithelial cells. Plucking of hair is no longer used, as we are generally able to get the reference DNA from either blood or the buccal swab.
- Swab for external genital region (labia)—RCMP have labelled as “outer vaginal” but actually mean the labia. If the area is dry, moisten a swab and wipe down either side of the labia.
- Swabs to take two duplicate vaginal wall samples—hold together and swab the walls of vaginal, across cervix and down into posterior fornix region (the cervix traps sperm and the fornix is an excellent reservoir)
- Vaginal smear and slide to take a smear using the duplicate vaginal swabs (both the swabs and the slide are returned to the lab). Do NOT disturb smear by using a microscope to examine it. Motility testing or vaginal wash samples are no longer obtained
- Anal swab for exterior anal region—helpful even if only vaginal penetration is reported as 30% of women have positive swabs although reporting no anal penetration
- Rectal swab—this must be obtained from above the pectinate line, the line just above the lowest 1/3 of the anal region where the keratinized epithelial tissue changes to mucosa/columnar epithelium. This is best exposed with the patient bearing down, dilating the anus.
- Documentation (NCR copies): consents, sexual assault history (provides areas of contact, recent consensual activity, activities since assault), sexual assault interview (appearance, timing of kit collection and emotional state, details of assault, excited utterances); forensic evidence record (types of samples collected and initials of officer, examiner); body Traumagram; genital Traumagrams (male/female); head/neck and hand Traumagrams if further detail is required or injuries won’t fit on body Traumagram; medical practitioner’s guide with instructions for personnel.

Some of the key items discontinued from the kit are the plastic garbage bags, the drop sheet and the equipment to collect plucked hairs. The plastic garbage bags were removed as plastic increases the risk of DNA degradation, especially if there are moist samples of clothing or swabs. Also removed is the “drop sheet”—the sheet the patients stood on as they undressed to collect trace evidence. There was very little yield with this practice in terms of evidence and the practice has been discontinued. Certainly if there was reason to suspect trace evidence on the clothing (e.g., broken glass, debris), the emergency staff could have the patient stand on a paper and include that in the kit if desired.

The technique for the bite mark swab collection has also been modified. The original technique called for two swabs—one moistened with water rolled over the teeth indentations and immediately followed by rolling a dry swab over the area. The water was found to “wick” the DNA upward from the indenta-

tions and then can be picked up by the dry swab. Only one swab is used in the new RCMP kit. Take one of the extra swabs provided in the kit, moisten one side of the cotton applicator with water and keep the other side dry. This same technique can be used for any dry stain. Wet stains only require a dry swab.

A second kit will also be available for toxicology testing if the patient had voluntary or involuntary incapacitation with drugs or alcohol. This kit will include two grey-stoppered vacutainers containing sodium fluoride and potassium oxalate, non-alcoholic swabs (e.g., betadine) and venipuncture equipment, as well as two sterile leak-proof urine containers. The preservative in the grey vacutainers prevents degradation of toxicologic materials (e.g., cocaine) and reduces need for refrigeration after the samples are obtained (LeBeau et al., 1999). The urine can be collected in the urine containers, but samples will need to be refrigerated. A preferred alternative is to transfer urine with a sterile syringe and large bore needle into two more grey vacutainers to prevent degradation. It is very important to obtain the blood and urine samples at approximately the same time (no more than 30 minutes apart) to allow the laboratory to calculate metabolism and anticipate metabolites. There will also be a form for blood and urine collection that summarizes medications the patient has taken, their symptoms and the type of drug screen requested, if known. An understanding of clinical toxidromes is helpful for emergency staff to both document the relevant symptoms and to recommend a more focused screen.

Summary

The BALD STEP mnemonic provides a standardized way to collect a broader range of injuries and physical findings typically seen with trauma and assault. It aids in reducing charting while providing a more comprehensive range of factors for which we should observe. The mnemonic can be handwritten onto any Traumagram or emergency chart for use with other types of trauma or assault patients or if working in areas without RCMP kits and documentation. Standardization of terms and documentation improves our invariable practice and allows for improved comparison of injury rates and findings across emergency departments. A major gap in injury research and knowledge is an understanding of patterns of injury and severity classifications with different types of assault (Sommers, 2006). These patterns of injury will help us to better anticipate those who may have been victims of violence, such as the woman I encountered many years before. Use of standardized terminology and documentation, such as with BALD STEP, is necessary before this work can be advanced. The integration of BALD STEP with the RCMP kit is an exciting first step toward improving our understanding of trauma and injury. ♦

About the author



Cathy Carter-Snell has worked mainly with trauma patients most of her career, in both emergency and intensive care. She has worked in forensic nursing for 11 years and is a certified sexual assault nurse examiner and emergency nurse, frequently serving as an expert witness in court. Cathy has won an international research award for her dissertation on injuries

with sexual assault, and a centennial award from CNA for her contributions to Canadian forensic nursing. She has developed two online programs for nurses at Mount Royal University—the ACCN Emergency Nursing certificate and the Forensic Studies certificate. She continues to teach in these programs, conduct research with the Forensic Research Network, and is transitioning out of her role as president and co-founder of the Forensic Nurses' Society of Canada.

References

- Apfelbaum, J.D., Shockley, L.W., Wahe, J.W., & Moore, E.E. (1998). Entrance and exit gunshot wounds: Incorrect terms for the emergency department? *Journal of Emergency Medicine, 16*(5), 741–745.
- Bariciak, C.D., Plint, A.C., Gaboury, I., & Bennett, S. (2003). Dating of bruises in children: An assessment of physician accuracy. *Pediatrics, 112*(4), 804–807.
- Carter-Snell, C.J. (2007). *Understanding women's risks for injury from sexual assault*. University of Alberta. Retrieved from <http://www.snellconsulting.org> or Canadian Nurses Association library.
- Gall, J.A., Goos, S.C., Payne-James, J.J., & Culliford, E.J. (2003). *Forensic medicine*. Edinburgh: Churchill Livingstone.
- Girardin, B.W., Faugno, D.K., Seneski, P.C., Slaughter, L., & Whelan, M. (1997). *Color atlas of sexual assault*. St. Louis: Mosby.
- Golden, G.S. (1994). Use of alternative light source illumination in bite mark photography. *Journal of Forensic Sciences, 39*(3), 815–823.
- Langlois, N.E., & Gresham, G.A. (1991). The ageing of bruises: A review and study of the colour changes with time. *Forensic Science International, 50*(2), 227–238. Retrieved from <http://search.ebscohost.com/login.aspx?direct=true&AuthType=ip,url,cookie,uid&db=cmedm&AN=1748358&site=ehost-live>
- LeBeau, M., Andollo, W., Hearn, W.L., Baselt, R., Cone, E., Finkle, B., ... Saady, J. (1999). Recommendations for toxicological investigations of drug-facilitated sexual assaults. *Journal of Forensic Sciences, 44*(1), 227–230.
- Lynnerup, N., Hjalgrim, H., & Eriksen, B. (1995). Routine use of ultraviolet light in medicolegal examinations to evaluate stains and skin trauma. *Medicine, Science and the Law, 35*(2), 165–168.
- Mosqueda, L., Burnight, K., & Liao, S. (2005). The life cycle of bruises in older adults. *Journal of the American Geriatrics Society, 53*(8), 1339–1343.
- National Forensic Nursing Institute. (2006). *T-blue swabs*. Retrieved from <http://www.nfni.org>
- Nelson, D.G., & Santucci, K.A. (2002). An alternate light source to detect semen. *Academic Emergency Medicine, 9*(10), 1045–1048.
- Sheridan, D.J., & Nash, K.R. (2007). Acute injury patterns of intimate partner violence victims. *Trauma Violence & Abuse, 8*(3), 281–289.
- Slaughter, L., Brown, C.R., Crowley, S., & Peck, R. (1997). Patterns of genital injury in female sexual assault victims. *American Journal of Obstetrics and Gynecology, 176*(3), 609–616.
- Sommers, M.S. (2006). Injury as a global phenomenon of concern in nursing science. *Journal of Nursing Scholarship, 38*(4), 314–320.
- Stephenson, T., & Bialas, Y. (1996). Estimation of the age of bruising. *Archives of Disease in Childhood, 74*(1), 53–55.
- Vogele, E., Pierce, M.C., & Bertocci, G. (2002). Experience with wood lamp illumination and digital photography in the documentation of bruises on human skin. *Archives in Pediatric & Adolescent Medicine, 156*, 265–268.